



Caritas Hyperbaric Oxygen Program

A Physician's Guide to Alberta's Centre for Hyperbaric Medicine

Hyperbaric Oxygen Therapy

[The Chambers](#)

[Transcutaneous Oxygen Measure \(TCOM\)](#)

[Patient Referral and Consultation Procedures](#)

[Beneficial Mechanisms Associated with Hyperbaric Oxygen Therapy](#)

[Indications for Hyperbaric Oxygen Therapy](#)

[Absolute Contraindications to HBOT](#)

[Relative Contraindications](#)

[Complications and Side Effects](#)

Case Studies

[Chronic Arterial Ulcer, left lateral ankle and lower leg with exposed bone](#)

[Compromised Skin Graft and Flap](#)

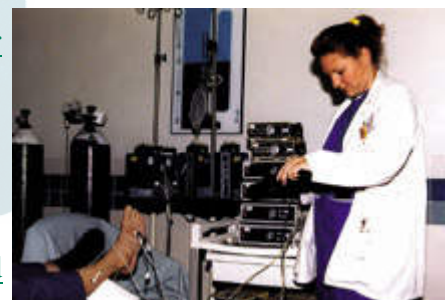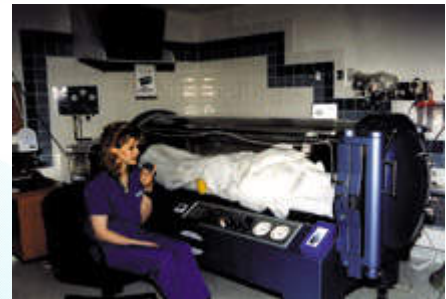[Treatment of a Problem Wound](#)

[Mandibulectomy Reconstructed with Vascularized Fibular Flap and Osseointegrated Implant Supported Prosthesis](#)

[Temporal Bone Resection Resulting in Loss of the Ear](#)

Hyperbaric Medicine Scientific Resources

Partners





Hyperbaric Oxygen Therapy

The Hyperbaric Oxygen Unit (HBO) at the Misericordia opened in April of 1994 in response to an initiative by the Craniofacial Osseointegration and Maxillofacial Prosthetic Rehabilitation Unit (C.O.M.P.R.U.) and Respiratory Care.

Hyperbaric Oxygen Therapy is the medical use of 100% oxygen at increased atmospheric pressure. This increased pressure provides more oxygen to the body than is possible under normal atmospheric conditions. Most treatments range between two and three atmospheres of pressure, typically referred to as “diving” because the pressure change closely approximates scuba diving. This increase of pressure dissolves more oxygen into body tissue and blood so that the body is saturated with more oxygen than normal to enhance healing.

There are 14 areas of pathology where efficacy is well documented by over 60 scientific studies (see reference list at the end of this guide). They are:

1. Air/Gas embolism
2. Carbon monoxide poisoning, smoke inhalation/cyanide poisoning
3. Clostridial myonecrosis
4. Crush injury, compartment syndrome, acute traumatic ischemias
5. Wound healing problems
6. Necrotizing soft tissue infections
7. Refractory osteomyelitis
8. Radiation tissue damage: Osteoradionecrosis
9. High risk post-irradiation dental extractions
10. Therapeutically irradiated patients requiring osseointegrated implants
11. Compromised Skin grafts and flaps
12. Decompression sickness
13. Exceptional blood loss anemia

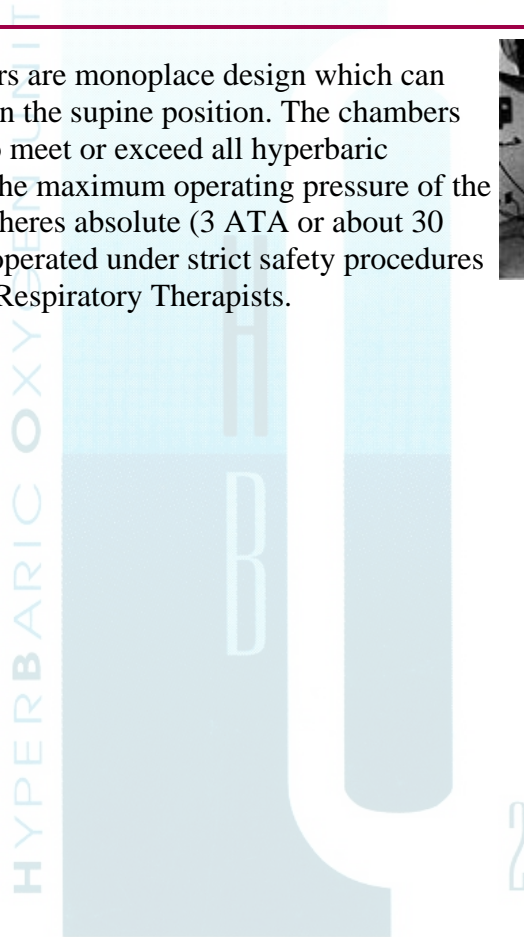
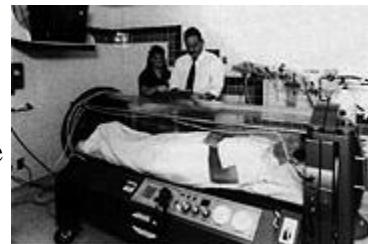Reperfusion Injuries - Frostbite



The Chambers

CARITAS HEALTH GROUP

The Hyperbaric chambers are monoplace design which can accommodate a patient in the supine position. The chambers are designed and built to meet or exceed all hyperbaric chamber safety codes. The maximum operating pressure of the chamber is three atmospheres absolute (3 ATA or about 30 PSIG). The chamber is operated under strict safety procedures by qualified Registered Respiratory Therapists.





Transcutaneous Oxygen Measure (TCOM)

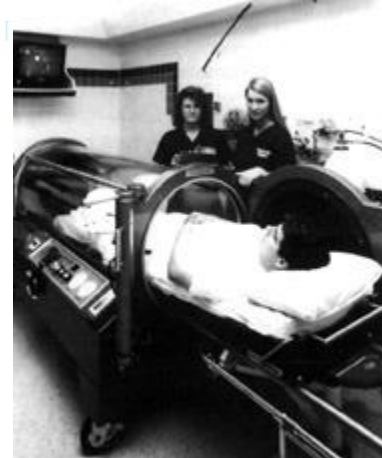HBO referrals for non-healing wounds may be assessed with transcutaneous oxygen measurements (TCOM).

The applications of TCOM include: assessment of healing potential of problem wounds, selection of surgical debridement and amputation levels and selection of appropriate candidates for Hyperbaric Oxygen Therapy.

Based on the results of a TCOM study, a determination can be made as to whether the wound will heal with HBO therapy.

Selecting appropriate candidates for HBO treatment can be accomplished with an oxygen challenge in conjunction with TCOM.

Only patients that have a documented poor to fair chance of healing spontaneously and demonstrate a good response to oxygen administration are treated with HBO.





Patient Referral and Consultation Procedures

All patients who are candidates for HBO are seen by a hyperbaric unit physician upon referral from their attending physician.

Hyperbaric oxygen therapy is offered as a referral and consultation service only. To refer a patient for evaluation during our normal working hours, Monday through Friday, 8:30 a.m. to 5:00 p.m., call:

Routine referrals - (780) 735-2768

Emergency - (780) 735-2627

HBO Unit - (780) 735-2537

Where hyperbaric oxygen therapy is considered appropriate, a treatment protocol and schedule will be established, and the hyperbaric consultants recommendations will be communicated to the referring physician. The referring/primary care physician will remain responsible for the patient's general medical management and will be updated from a hyperbaric perspective, as appropriate, by the H.B.O. team. Out-of-town patients may be referred to an appropriate local physician at the discretion of the referring physician. Patients with chronic conditions such as osteoradionecrosis and other wound healing conditions account for the majority of patients being treated at this facility. These patients are typically ambulatory, but have conditions that require a 4 - 8 week treatment period. These patients account for 80 - 90% of H.B.O. chamber utilization.

In distinction to the chronic conditions, the acute conditions require a small number of H.B.O. treatments (usually between 1 - 5 treatments). Patients with acute life threatening conditions, requiring critical care support should be directly referred to the On Call physician in the Emergency department.



Beneficial Mechanisms Associated with Hyperbaric Oxygen Therapy

Several beneficial mechanisms are associated with intermittent exposure to hyperbaric doses of oxygen. Either alone, or more commonly in combination with other medical and surgical procedures, these mechanisms serve to enhance the healing or toxic process of treatable conditions.

1. Hyperoxygenation provides immediate support to poorly perfused tissue in areas of compromised blood flow. The elevated pressure within the hyperbaric chamber results in a 10 - 15 fold increase in plasma oxygen concentration. This translates to arterial oxygen values of between 1,500 and 2,000 mmHg, thereby producing a four-fold increase in the diffusing distance of oxygen from functioning capillaries. While this form of hyperoxygenation is only a temporary measure, it will serve to buy time and maintain tissue viability until corrective measures can be implemented or a new blood supply is established.
2. Neovascularization represents an indirect and delayed response to hyperbaric oxygen exposure. Therapeutic effects include enhanced fibroblast proliferation, neof ormation of collagen and capillary angiogenesis in areas of sluggish neovascularization such as late radiation damaged tissue, refractory osteomyelitis and chronic wounds.
3. Hyperoxia-enhanced antimicrobial activity has been demonstrated at a number of levels. Hyperbaric oxygen causes toxin inhibition and toxin inactivation in Clostridial myonecrosis infections (gas gangrene). Hyperoxia enhances phagocytosis and white cell oxidative killing, and has been shown to enhance aminoglycoside activity. Recent research has demonstrated a prolonged post-antibiotic effect, when hyperbaric oxygen is combined with tobramycin against *Pseudomonas aeruginosa*.
4. Direct pressure utilizes the concept of Boyle's Law to reduce the volume of intravascular or other free gas. For more than a century this mechanism has formed the basis of hyperbaric oxygen therapy as the standard of care for decompression sickness and cerebral arterial gas embolism (CAGE). Commonly associated with divers, CAGE is a frequent iatrogenic event in modern medical practice. It results in significant morbidity and mortality and remains grossly underdiagnosed.
5. Hyperoxia-induced vasoconstriction is another important mechanism. It occurs without component hypoxia and is helpful in managing intermediate compartment syndrome and other acute ischemias in injured extremities, and reducing interstitial

edema in grafted tissue. Studies in burn wound applications have indicated a significant decrease in fluid resuscitation requirements when HBO therapy is added to standard burn wound management protocols.

6. Attenuation of reperfusion injury is the most recent mechanism to be discovered. Much of the damage associated with reperfusion is brought about by the inappropriate activation of leukocytes. Following an ischemic interval the total injury pattern is the result of two components: a direct irreversible injury component from hypoxia, and an indirect injury which is largely mediated by the inappropriate activation of leukocytes. Hyperbaric oxygen reduces the indirect component of injury by preventing the inappropriate activation of leukocytes. The net effect is the preservation of marginal tissues that would otherwise be lost to ischemia-reperfusion injury.





Indications for Hyperbaric Oxygen Therapy

1. Cerebral Arterial Gas Embolism

decompression and iatrogenically induced

A major life-threatening event, with significant morbidity and mortality, CAGE can occur following reductions in ambient pressure (in divers and aviators), traumatically, in penetrating chest injuries, and, most commonly, in the clinical setting secondary to invasive diagnostic or therapeutic procedures.

Cost Impact:

HBOT is the primary choice of treatment for CAGE. HBOT decreases the high mortality and prevents or mitigates neurological sequelae. HBOT is a cost effective treatment considering the potential costs of rehabilitation from a neurological event.

2. Carbon Monoxide Poisoning

smoke inhalation and cyanide

Carbon monoxide is one of the most common causes of poisoning in Canada. In its subtle forms, the diagnosis is easily missed. A new application for the phenomenon of clinical relapse following non-H.B.O. treatment and its potential long-term sequelae has increased the importance of early referral for hyperbaric evaluation.

Cost Impact:

The modest cost of HBO therapy for CO poisoning represents a potentially large dollar savings when compared to the cost of treatment for delayed neurological sequelae.

3. Clostridial Myonecrosis

gas gangrene

Anaerobic infections are among the most challenging infectious diseases. Optimum management of Clostridial Perfringens infections is well established. The combination of antibiotic therapy, surgical debridement, and hyperbaric oxygen will reduce mortality and limit tissue loss.

Cost Impact:

The addition of HBOT to the treatment regime reduces morbidity and improves the level of amputation in affected limbs, thus justifying the cost.

4. Crush Injury: Other Acute Ischemias

compartment syndrome

Hyperbaric oxygen has been observed to arrest the progression of a skeletal muscle compartment syndrome. Its use is based upon a number of mechanisms and serves to limit tissue necrosis. While not proposed as a replacement for surgical decompression in severe cases, hyperbaric oxygen has been used effectively in intermediate settings and in other acute ischemias to preserve marginally perfused tissue.

Cost Impact:

The cost of decompression of compartment syndrome by HBO therapy is about one fourth that of surgical intervention. The cost of HBO therapy is small relative to that of treating the complications of acute traumatic ischemias.

5. Problem (non-healing) Wounds

Problem wounds are defined as wounds that fail to show improvement in four weeks or complete healing in eight weeks despite standard medical and surgical intervention. These may include diabetic foot ulcers, vascular insufficient wounds, and non-healing traumatic wounds. All of these wounds have the underlying problems of tissue hypoxia. Therefore, HBO is an adjunctive therapy in treatment of hypoxic wounds by producing effects of fibroblast proliferation, neo-vascularization and leukocyte oxidative killing. Recent literature has shown reduction in major amputation for patients with diabetic foot ulcers. HBO for problem wounds should be undertaken with the clear understanding that it must be part of a vigorous and coordinated multidisciplinary team approach to wound care.

Cost Impact:

The treatment and follow-up costs for HBO and wound care for healing are significantly lower than those who undergo major amputation and rehabilitation.

6. Necrotizing Soft Tissue Infections

(Subcutaneous Tissue, Muscle, Fascia):

Hyperbaric oxygen is used as an adjunct to surgical debridement and antibiotic therapy. Limited clinical trials have indicated reduced mortality, and a reduction in the need for repeated debridements when hyperbaric oxygen is added to surgical and medical management.

Cost Impact:

These infections are associated with high mortality and morbidity. The addition of HBOT, in many cases, has reduced the number of surgical interventions and shortened hospital stay.

7. Refractory Osteomyelitis

Osteomyelitis is essentially a surgical disease. Appropriate antibiotics and debridement are effective in the majority of cases.

Where bone infections persist, adjunctive hyperbaric oxygen has been demonstrated to help the healing process in

a high percentage of otherwise refractory cases, through a number of direct and indirect mechanisms.

Cost Impact:

When used according to guidelines and as an adjunct to adequate surgical care and antibiotic therapy, HBOT is clinically efficacious and cost effective. In one review, cost effectiveness was five-fold in favor of using adjunctive HBOT for chronic refractory osteomyelitis.

8. Osteoradionecrosis *mandible*

Laboratory investigations and recently reported controlled trials have demonstrated the clinical and cost-effective advantages of hyperbaric oxygen therapy in effectively managing this particularly difficult problem.

Cost Impact:

Osteoradionecrosis, at best, is an extremely painful and debilitating condition. It can be potentially fatal if a major vessel becomes involved. The introduction of HBOT to the treatment plan can have a significant impact on a potentially long and expensive treatment course.

9. Radiation Tissue Injury

Based upon laboratory and clinical studies of osteoradionecrosis, the use of hyperbaric oxygen has been extended to late radiation change in soft tissue, where similar pathophysiologies, therapeutic and cost saving responses are reported.

Cost Impact:

The incorporation of HBOT to the treatment plan can have a significant impact on surgical intervention, standard drug therapy and a potentially long and expensive treatment course.

10. Therapeutically Irradiated Patients requiring Osseointegrated Implants or High Risk Dental Extractions

HBO is central to the management of patients undergoing implantation in irradiated bone. Dental extractions in these patients often lead to non-healing wounds.

Cost Impact:

It has been found that in irradiated patients, the osseointegrated implant failure rate was 54%, whereas in the irradiated and HBOT managed group the failure rate was reduced to 8%.

11. Compromised Skin Grafts and Flaps *preparation for grafting*

While not indicated in non-compromised settings, postoperative hyperbaric oxygen has been particularly helpful in host compromised patients where graft or flap viability is in question, and in preparing the poorly responding wound for coverage.

Cost Impact:

A failed flap or graft may conservatively cost up to \$30,000 in additional care. HBOT can reduce this extra cost by contributing to the salvage of transplanted tissue.

12. Decompression Sickness

The occupational disease of divers, aviators and tunnel workers is no longer limited in presentation to coastal regions and military institutions. With more recreational divers flying to and from various dive sites, the potential for this illness must be considered, regardless of geographical location.

Cost Impact:

Untreated, DCS can result in permanent nerve, spinal cord, or brain damage. HBOT is cost effective considering the limited number of persons who acquire DCS, balanced against the expensive support of those not treated.

13. Acute Exceptional Blood Loss Anemia

Hyperbaric oxygen is used to extend the physiologic limits of the cardiovascular system in those patients who cannot or will not accept blood transfusions during acute and severe episodes of blood loss anemia.

Cost Impact:

In this difficult clinical challenge, a course of HBOT would represent additional cost, but could be lifesaving.

14. Reperfusion Injuries: Frostbite

The pathophysiology for frostbite is similar to that of other reperfusion injuries such as crush injury, compartment syndrome, and acute traumatic ischemia. Tissue destruction results from the primary injury where tissue damage is unrepairable, or by secondary injury during reperfusion. Most tissue loss is from the body's inability to handle the primary injury thus resulting in secondary injury. As the tissue receives the first available oxygen it is converted to toxic radicals which are overwhelmed causing a vasoconstriction, thrombosis and ischemic swelling of soft tissues such as muscles. Delivery of oxygen and nutrients to the tissues is disrupted due to the stasis of the microcirculation.

During rewarming, oxygen demands are greatest therefore the primary and most important role is hyperoxygenation to maintain tissue viability. The key to a successful outcome with Hyperbaric oxygen therapy is when it is applied during the ischemic phase within hours of injury.

Cost Impact:

Hyperbaric Oxygen Therapy when applied during the ischemic phase will decrease edema and congestion limiting tissue damage. HBOT hastens demarcation for nonviable tissue and prevents the extension of infection from necrotic tissue to the adjacent severely injured tissue. The cost effectiveness is in promoting wound healing and decreasing the number of surgical amputations.



Absolute Contraindications to HBO Therapy

Untreated Pneumothorax

A patient presenting with an undrained pneumothorax in a pressurized hyperbaric chamber is always considered a concern. If the pneumothorax tensions at pressure, decompression will be extremely hazardous and potentially life-threatening. A patient with a pre-existing pneumothorax should have a chest tube inserted prior to pressurization, and, if a pneumothorax occurs under pressure a chest tube should be inserted prior to decompression. It is prudent to obtain a chest x-ray after the placement of a subclavian line, to rule out the occurrence of pneumothorax before a patient is pressurized in the chamber.

Doxorubivin (AdrimycinR) - Antineoplastic agent

While HBOT was being investigated as a non-surgical “antidote” for tissue damage caused by the extravasation of Doxorubicin, it was discovered that this drug combined with HBOT caused an 87% mortality rate in lab rats. This mortality rate did not vary with reduced HBOT frequency. A patient should be discontinued from Doxorubicin at least one week prior to beginning HBOT.

Disulfiram (AntabuseR) - Antialcoholic

Disulfiram was found to block both pulmonary and central nervous system oxygen toxicity. However, additional work revealed that the body’s superoxide dismutase (SOD) was reduced by Disulfiram. The SOD system is the body’s main defense against oxygen toxicity. Therefore, Disulfiram use is contraindicated during HBOT in all cases except Carbon Monoxide poisoning (single treatment). Patients in need of serial HBO treatments should be discontinued from Disulfiram at least one week prior to commencing HBOT.

Cis-Platinum - Antineoplastic

Cis-Platinum is an agent that is useful in the control of a number of cancers by interfering with DNA synthesis and subsequent delays in fibroblast production and collagen synthesis. The incompatibility with HBOT occurred because the wound breaking strength was found to be considerably less in the HBOT/Cis-Platinum group than in the control group. HBOT should be delayed until the patient has been

discontinued from Cis-Platinum for at least one week.

Mafenide Acetate (SulfamylonR) - Antibacterial

This antibacterial cream was found useful in suppressing infection in burn patients. However, Mafenide is also a carbonic anhydrase inhibitor which tends to encourage carbon dioxide buildup that causes a peripheral vasodilator. A synergistic detrimental effect occurs when this effect is combined with the central vasoconstriction caused by HBOT. Patients, who are being prepared for HBOT and are receiving Mafenide cream therapy, should have all of the cream removed by rubbing. Silver Sulfadiazine (FlamazineR) is an effective substitute and is compatible with HBOT.

HYPERBARIC OXYGEN UNIT





Relative Contraindications



With the following conditions, patients may be treated with caution:

- Upper respiratory infections and chronic sinusitis
- Seizure disorders
- Emphysema and carbon dioxide retention
- High Fever
- History of spontaneous pneumothorax
- History of thoracic surgery
- History of surgery for otosclerosis
- Viral infections
- Congenital spherocytosis
- History of optic neuritis

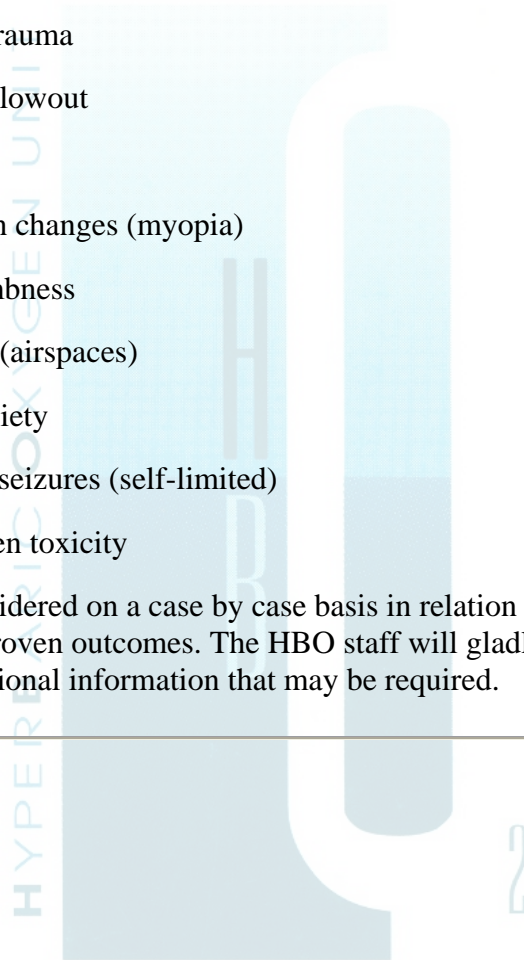


Complications and Side Effects



- Barotrauma of the ear
- Pulmonary barotrauma
- Round window blowout
- Sinus squeeze
- Temporary vision changes (myopia)
- Acute finger numbness
- Dental problems (airspaces)
- Confinement anxiety
- Oxygen induced seizures (self-limited)
- Pulmonary oxygen toxicity

HBOT referrals are considered on a case by case basis in relation to all contraindications, potential benefits, and proven outcomes. The HBO staff will gladly provide the referring physician with any additional information that may be required.





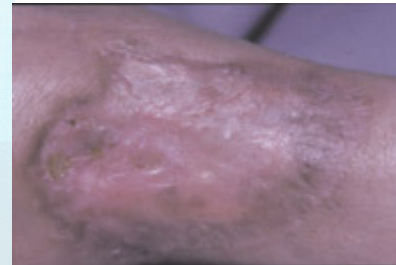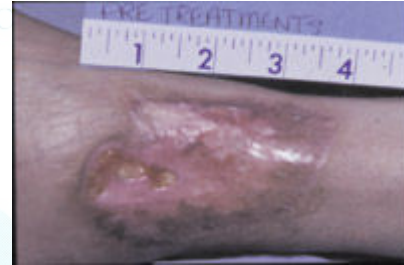Case Studies

Chronic Arterial Ulcer left lateral ankle and lower leg with exposed bone

49 year old female with history of Lupus Vasculitis. Patient developed areas of necrosis of the skin and subcutaneous tissue at the lateral aspect lower leg as well as the lateral ankle. The patient required I.V. antibiotics and underwent an extensive debridement and split thickness skin graft. Angiograms done pregrafting revealed poor blood flow to the lower extremity with poor distal run off. If graft failed, the patient would be scheduled for a below knee amputation. Four months post grafting the patient was referred to the Hyperbaric Unit with a failed graft and nonhealing wound.

Assessment revealed an ulcerated area over and proximal to left lateral malleolus with areas of full thickness skin loss down to the malleolus and distal tibular shaft. Transcutaneous Oxygen mapping indicated areas adjacent to the wound site to be hypoxic with partial pressures below 30 mmHg. The wound would have a poor chance of healing in an ambient environment. HBOT was initiated, using 90 minute treatment protocol of 2.0 atmospheres absolute pressure five days per week for a total of 50 treatments. Moist wound care with IntraSite Gel® and Allevyn® were applied changed Q3D.

Completion of 50 HBOT resulted in granulation tissue formation and epithelization over the malleolus and tibular shaft with salvage of the leg.



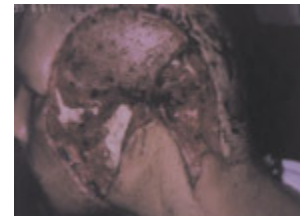


Case Studies

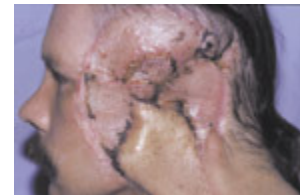Compromised Skin Graft and Flap



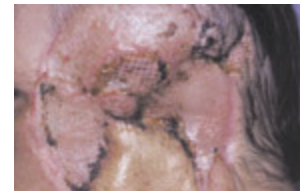This 42 year old male diagnosed with a basal cell carcinoma adjacent to his left ear. Patient underwent an extensive left sided resection involving the temporal bone and adjacent soft tissue, parotid gland, and selective node dissection. A trapezius flap and a split thickness tissue graft, from the thigh were used to graft over the temporal bony region. Five days post skin graft and flap the edges appeared slightly dusky. Evidence of increased ischemia and infection in the flap was noted on day ten. The graft and flap continued to fail despite aerobic and anaerobic coverage. On the twentieth day post grafting extensive debridement of the flap and graft was done due to failure.



Patient was then referred for HBOT for Compromised skin graft and flap. HBOT was initiated using a 90 minute treatment with BID treatment for first two days, remaining treatments on a daily basis.



Post tenth HBOT a good bed of granulation tissue was formed and partial re-grafting was done. After the twentieth HBOT re-grafting was completed. Patient received 26 HBOT with complete healing of the graft and flap.

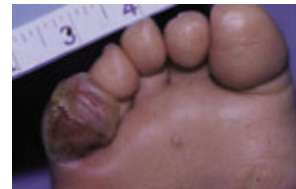



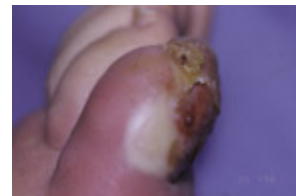Case Studies

Treatment of a Problem Wound

43 year old male, IDDM x 30 yrs. Presented to hospital with an infected right 5th toe and cellulitis, as a result of a tight ski boot.



Patient started on IV antibiotics, HBO therapy, appropriate wound care and offloading.

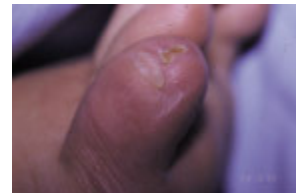

No surgical interventions were done. Bone scan showed an osteomyelitis.

Transcutaneous oxygen mapping was performed. The results indicated the wound would not heal in an ambient environment as the partial pressures of oxygen were far below 30 mmHg.

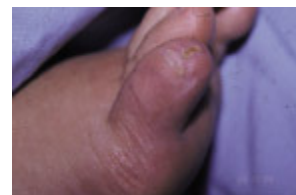Wound care treatment was moist wound healing with debridement of wound and offloading the pressure. Dressings consisted of an Intrasite® Gel to base of wound with an Allevyn® dressing. A light compression with a Tubigrip® was used to decrease the edema to the leg. The dressings were changed every second day. A Darco® Boot was fitted to the patient's foot for offloading of pressure at the wound site.

Patient underwent a course of 30 HBO treatments daily using a 90 minute treatment interval at pressures of 2.5 atmospheres absolute.



Appearance of the wound after completion of HBO. The result was excellent salvage of the leg and toe. Patient continued on oral antibiotics for 1 month.

2 month follow-up: healing is complete.

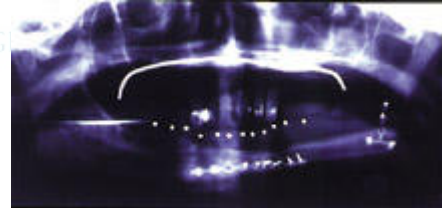




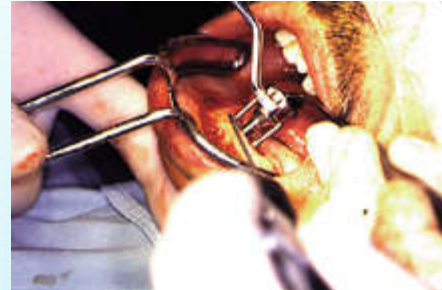Case Studies

Mandibulectomy Reconstructed with Vascularized Fibular Flap and Osseointegrated Implant Supported Prosthesis

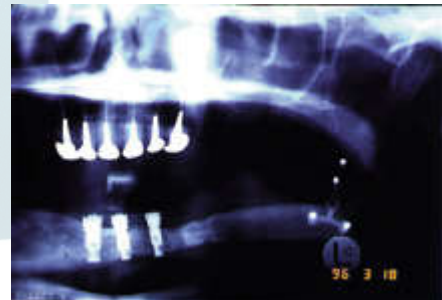This 42 year old man was diagnosed with squamous cell carcinoma of the tongue. He was treated with chemotherapy and both external beam and interstitial radiation therapy. He developed an osteoradionecrosis of the left mandible. The necrotic bone was resected and a vascularized fibular flap was used to reconstruct the mandible.



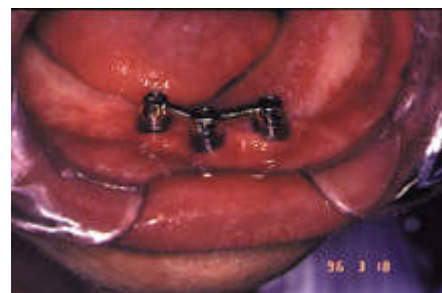To provide the patient with a mandibular prosthesis, osseointegrated implants were placed into the reconstructed mandible. The implants had to be placed into both native mandible and the vascularized fibula. As the native mandible had been in the field of radiation therapy, 20 hyperbaric treatments were provided prior to implant placement and immediately after implant placement a further 10 treatments were undertaken. The hyperbaric treatment consisted of 90 minutes at 2.5 atmospheres absolute once a day.



The reconstructed mandible, showing osseointegrated implants in both native mandible and vascularized fibula. Endodontic treatment together with posts and cores were used to support an overdenture in the maxilla.

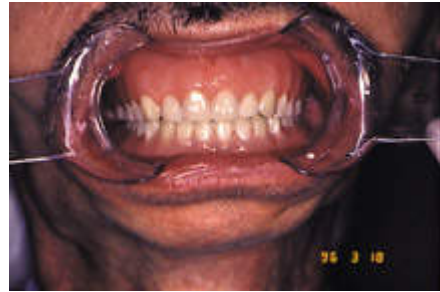

The bar superstructure used to retain the mandibular prosthesis.



Anterior view of the completed mandibular and maxillary prosthesis.

The prosthesis has been in function for almost three years without major incident.



CARITAS HEALTH GROUP

HYPERBARIC OXYGEN UNIT

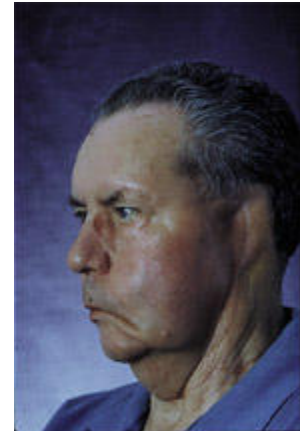



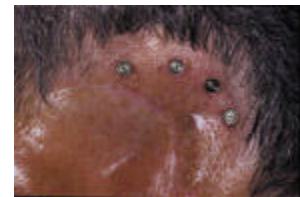Case Studies

Temporal Bone Resection resulting in loss of the ear

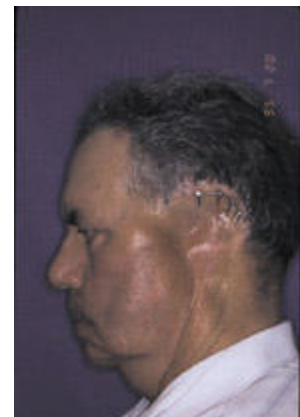This 68 year old man was diagnosed with squamous cell carcinoma of the left external auditory meatus. The temporal bone resection resulted in loss of the left ear. Following the resection, the patient was treated with therapeutic radiation.



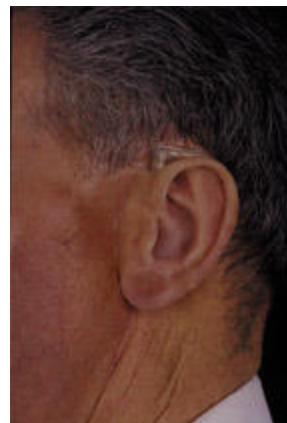
The surgery and radiation therapy precluded any form of autogenous reconstruction. Craniofacial oseointegrated implants were used to retain an auricular prosthesis. As the patient had been therapeutically irradiated, hyperbaric treatment was undertaken. Twenty dives prior to implant placement and ten dives after implant placement were administered. The hyperbaric treatment consisted of 90 minutes at 2.5 atmospheres absolute once a day.



A bar superstructure was connected to the percutaneous titanium abutments. A clip system within the ear prosthesis allowed the prosthesis to be retained on to the bar superstructure.



A close-up view of the auricular prosthesis retained on the craniofacial osseointegrated implants.



HYPERBARIC OXYGEN UNIT





Hyperbaric Medicine Scientific Resources



Textbooks

Hyperbaric Medicine Practice
E.P. Kindwall, Editor 1994
Best Publishing Company, Flagstaff, Arizona
ISBN 0-941332-29-2

Textbook of Hyperbaric Medicine
2nd Revised Edition, K. K. Jain 1996
Hogrefe and Huber Publishers
Seattle, Washington
ISBN 0-88937-127-X

References

i. GENERAL REVIEW

Tibbles, Patrick, et al: **Hyperbaric Oxygen Therapy Review Article**. New England Journal of Medicine 1996; 334:25.

Camporesi Em: **Use of Hyperbaric Oxygen in Critical Care**. Critical Care State of the Art. Eds. Lumb PD and Shoemaker WC 1990, Society of Critical Care Medicine Fulleton, California.

Weiss LD, Van Meter KW: **The Applications of Hyperbaric Oxygen Therapy in Emergency Medicine**. American Journal of Emergency Medicine 1992;10(6):558-568.

Kindwall EP: Uses of Hyperbaric Oxygen Therapy in the 1990's. Cleveland Clinic Journal of Medicine 1992;59(5):517-528.

ii. PLASTIC SURGERY (SKIN GRAFTS AND SKIN FLAPS)

Kindwall EP, Gottlieb LJ, Larson DL: **Hyperbaric Oxygen Therapy in Plastic Surgery: A Review Article**. Plastic and Reconstructive Surgery 1991; 88(5):989-908

Zamboni WA, Roth AC, Russell RC, et al: **The Effect of Acute Hyperbaric Oxygen Therapy on Axial Pattern Skin Flap Survival When Administered During and After Total Ischemia**. Journal of Reconstructive Microsurgery 1989;

5(4):343-345.

Zamboni WA, Roth AC, Russell RC, et al: **Morphologic Analysis of the Microcirculation During Reperfusion of Ischemic Skeletal Muscle and the Effect of Hyperbaric Oxygen.** Plastic and Reconstructive Surgery 1993 May; 9(16):110-23

Tai YJ, Birely BC, IM MJ et al: **The Use of Hyperbaric Oxygen for Preservation of Free Flaps.** Annals of Plastic Surgery 1992;28(3):284-287.

Bowersox JC, Strauss MB, Hart GB. **Clinical experience with hyperbaric oxygen therapy in the salvage of ischemic skin flaps and grafts.** J Hyperb Med 1986;1:141-9

iii. CARBON MONOXIDE POISONING

Thom SR: **Functional Inhibition of Leukocyte B2 Integrins by Hyperbaric Oxygen in Carbon Monoxide-Mediated Brain Injury in Rats.** Toxicology and Applied Pharmacology 1993; 123:248-256.

Myers RAM: **Carbon Monoxide Poisoning.** Clinical Management of Poisoning and Drug Overdose 2nd Edition Haddad & Robinson 1990: Chpt 74 1139-1152. RA 1211 C64 1990

Runciman WW, Gorman DF. **Carbon Monoxide Poisoning: From Old Dogma to New Uncertainties.** The Medical Journal of Australia 1993;158:439-440.

Gorman DF, Clayton D, Gilligan JE, et al. **A Longitudinal Study of 100 Consecutive Admissions for Carbon Monoxide Poisoning to the Royal Adelaide Hospital.** Anaesthesia and Intensive Care 1992;20(3):311-316.

Piantadosi C: **The Role of Hyperbaric Oxygen in Carbon Monoxide, Cyanide, and Sulphide Intoxication.** Problems in Respiratory Care 1991;4(2):215-223.

Meyer GW, Hart GB, Strauss MB: **Hyperbaric Oxygen Therapy for Acute Smoke Inhalation Injuries.** Postgraduate Medicine 1991;89(1):221-223.

Van Hoesen KB, Camporesi EM, Moon RE, et al: **Should Hyperbaric Oxygen be Used to Treat the Pregnant Patient for Acute Carbon Monoxide Poisoning.** JAMA 1989;261(7):1039-1044.

iv. ACUTE MYOCARDIAL ISCHEMIA

Thomas MP, Brown LA, Sonseller DR, et al: **Myocardial Infarct Size Reduction by the Synergistic Effect of Hyperbaric Oxygen and Recombinant Tissue Plasminogen Activator.** American Heart Journal 1990;120(4):791-800.

Swift PC, Turner JH, Oxer HF, et al.: **Myocardial Hibernation Identified by Hyperbaric Oxygen Treatment and Echocardiography in Postinfarction Patients: Comparison with Exercise Thallium Scintigraphy.** American Heart Journal 1992;124:1151-1158.

Ellestad MH, Shandling AH, Hart GB, et al: **Hyperbaric Oxygen and Thrombolysis in Myocardial Infarction**. The "Hot MI" Study. Supplement to Circulation 1992;86(4):ABST #184, New Orleans.

Sterling DL, Thornton JD, Swafford A, et al.: **Hyperbaric Oxygen Limits Infarct Size in Ischemic Rabbit Myocardium in Vivo**. Circulation 1993;88(4)1. pp 1931

v. CEREBRAL ARTERIAL GAS EMBOLISM

Moon RE: **Treatment of Gas Bubble Disease**. Problems in Respiratory Care 1991; 4(2):232-252.

Kol S, Ammar R, Weisz G, et al: **Hyperbaric Oxygenation for Arterial Air Embolism During Cardiopulmonary Bypass**. Annals of Thoracic Surgery 1993;55:401-403.

Pelaia P, Rocco M, Volturo P, et al: **Arterial Air Embolism During Cardiopulmonary Bypass: Twelve Years Experience**. Journal of Hyperbaric Medicine 1992; 7(2):115-121.

Dutka AJ: **A Review of the Pathophysiology and Potential Application of Experimental Therapies for Cerebral Ischemia to the Treatment...** Undersea Biomedical Research 1985;12(4):403-421.

Lar LW, Lai LC, Rem LW, et al.: **Massive Arterial Air Embolism During Cardiac Operation: Successful Treatment in a Hyperbaric Chamber Under 3 ATA**. The Journal of Thoracic and Cardiovascular Surgery 1990;100(6):928-930.

vi. DECOMPRESSION SICKNESS

Moon RE. **Treatment of Gas Bubble Disease**. Problems in Respiratory Care 1991; 4(2):232-252.

Melamed Y, Shuypak A, Bitterman H: **Medical Problems Associated with Underwater Diving**. New England Journal of Medicine 1992;326(1):30-35

vii. OSTEORADIONECROSIS

Marx RE, Ehler WJ, Tayapongasak P, et al.: **Relationship of Oxygen Dose to Angiogenesis Induction in Irradiated Tissue**. The American Journal of Surgery 1990;160:519-524.

Marx R: **Osteoradionecrosis: A New Concept of its Pathophysiology**. Journal of Oral and Maxillofacial Surgery 1993;41:283-288.

Granström G, Devge C, Tjellström: **Laser Doppler Flowmetry for the Intraosseous Blood Flow Measurement After Irradiation, Bone Grafting and Hyperbaric Oxygen Treatment**. The International Journal of Oral & Maxillofacial Implants 1992;7(1):15-25.

Granström G, Tjellström A, Brånemark, P, et al.: **Bone-Anchored Reconstruction**

of the Irradiated Head and Neck Cancer Patient. Otolaryngology-Head and Neck Surgery 1993;108(4):334-343.

Granström G, Tjellström A, Brånemark, P-I: **Osseointegrated Implants in Irradiated Bone: A Case-Controlled Study Using Adjunctive Hyperbaric Oxygen Therapy.** Journal of Oral and Maxillofacial Surgery 1999; 57: 493-499.

Dempsey James, Hynes Nick, Smith Teresa, Sproat Janet E: **Cost effectiveness analysis of hyperbaric therapy in osteoradionecrosis.** Can J Plast Surg Vol 5 No 4 Winter 1997; 221-229.

viii. OSTEORADIONECROSIS PREVENTION

Marx RE, Johnson RP, Kline SN: **prevention of osteoradionecrosis: A Randomized Prospective Clinical Trial of Hyperbaric Oxygen Versus Penicillin.** JADA 1985;111:49-54

ix. SOFT TISSUE RADIONECROSIS

Kindwall EP: **Hyperbaric Oxygen's Effect on Radiation Necrosis.** Clinics in Plastic Surgery 1993;20(3) 473-483.

Williams J, Clarke D, Dennis WA, et al.: **The Treatment of Pelvic Soft Tissue Radiation Necrosis with Hyperbaric Oxygen.** Am J. Obstet Gynecol 1992;167(2):412-416.

Feldmeier JJ, Heimbach RD, Davolt DA, et al: **Hyperbaric Oxygen as an Adjunct Treatment for Severe Laryngeal Necrosis: A Report of Nine Consecutive Cases.** Undersea & Hyperbaric Medicine 1993;20(4) pages 329-35

Rijkmans BG, et al.: **Successful Treatment of Radiation Cystitis with Hyperbaric Oxygen.** Eur Urol 1989; 16: 354-356.

x. DIABETIC FOOT INFECTIONS

Baroni G, Porro T, Faglia E, et al.: **Hyperbaric Oxygen in Diabetic Gangrene Treatment.** Diabetes Care 1987; 10(1):81-86.

Oriani G, Meazza D, Favales F, et al.: **Hyperbaric Oxygen Therapy in Diabetic Gangrene.** Journal of Hyperbaric Medicine 1990;5(3):171-175.

Doctor N, Pandya S, Supe A: **Hyperbaric Oxygen Therapy in Diabetic Foot.** Journal Postgrad Medicine 1992; 38(3):112-114.

Cianci P, Hunt TK: **Adjunctive Hyperbaric Oxygen Therapy in Treatment of Diabetic Foot Wounds. The Diabetic Foot.** Fifth Edition 1993; Chpt 14:306-319.

Ciani P, Hunt TK: **Long-term results of aggressive management of diabetic foot ulcers suggest significant cost effectiveness.** Wound Repair and Regeneration Vol. 5, No. 2 pp. 141-146.

Faglia E, et al: **Adjunctive systemic hyperbaric oxygen therapy in treatment of**

severe prevalently ischemia diabetic foot ulcers. *Diabetes Care* 1996; 19:1338

xi. NECROTIZING SOFT TISSUE INFECTIONS

Zamboni WA, Riseman JA, Kucan JO: **Management of Fournier's Gangrene and the Role of Hyperbaric Oxygen.** *Journal of Hyperbaric Medicine* 1990;5(3):177-186.

Per Riegels-Neilsen P, et al.: **Fournier's Gangrene: 5 Patients Treated with Hyperbaric Oxygen.** *The Journal of Urology* 1984;132:918-920.

Eltorai I, Hart GB, Strauss MB, et al.: **The Role of Hyperbaric Oxygen in the Management of Fournier's Gangrene.** *Int Surg* 1986;71:53-58.

Hirn M: **Hyperbaric Oxygen in the Treatment of Gas Gangrene and Perineal Necrotizing Fasciitis.** *European Journal of Surgery Supplement* 1993(570);1-36.

Bakker DJ: **Necrotizing Soft Tissue Infections.** *Journal of Hyperbaric Medicine* 1987;2(3): 161-168.

Riseman, Jay A., Zambonie, William A. et al: **Hyperbaric oxygen therapy for necrotizing fasciitis reduces mortality and the need for debridements.** *Surgery* No. 1990;847-850.

xii. CRUSH INJURY/ACUTE ISCHEMIAS

Strauss M, Hargens AR, Gershuni DG, et al: **Delayed use of Hyperbaric Oxygen for Treatment of a Model Anterior Compartment Syndrome.** *Journal of Orthopaedic Research* 1986;4:108-111.

Skyhar MJ, Hargens AR, Strauss MB, et al: **Hyperbaric Oxygen Reduces Edema and Necrosis of Skeletal Muscle in Compartment Syndromes Associated with Hemorrhagic Hypotension.** *The Journal of Bone and Joint Surgery* 1986;68-A(8):1218-1224.

Nylander G, Otamiri T, Lewis DH, et al: **Lipid Peroxidation Products in Postischemic Skeletal Muscle and After Treatment with Hyperbaric Oxygen.** *Scandinavian Journal of Plastic Reconstructive Surgery and Hand Surgery* 1989;23:97-103.

Nylander G, Nordstrom H, Lewis D, et al: **Metabolic Effects of Hyperbaric Oxygen in Postischemic Muscle.** *Plastic and Reconstructive Surgery* 1987;79(1):91-97.

Nylander G, Nordstrom H, Franzen L, et al.: **Effects of Hyperbaric Oxygen Treatment in Post-Ischemic Muscle (A Quantitative Morphological Study).** *Scandinavian Journal of Plastic and Reconstructive Surgery* 1988;22:31-39.

xiii. GAS GANGRENE

Hirn M, Niinikoski J, Lehotonen OP: **Effect of Hyperbaric Oxygen and Surgery**

on **Experimental Multimicrobial Gas Gangrene**. Eur Surg Res 1993;25:265-269.

Hirn M: **Hyperbaric Oxygen in the Treatment of Gas Gangrene and Perineal Necrotizing Fasciitis**. European Journal of Surgery Supplement 1993(570):1-36.

Hart GB, Strauss MB: **Gas Gangrene – Clostridial Myonecrosis: A Review**. Journal of Hyperbaric Medicine 1990;5(2):125-144.

Bakker DJ: **Clostridial Myonecrosis. In Problem Wounds, The Role of Oxygen**, Eds. Davis JC and Hunt TK 1988:153-172 Elsevier Publishing Company, New York.

xiv. DEEP FUNGAL INFECTIONS

Ferguson BJ, Mitchell TG, Moon R, et al: **Adjunctive Hyperbaric Oxygen for Treatment of Rhinocerebral Mucormycosis**. Review of Infectious Diseases 1988;10(3):551-559.

Couch L, Theilen F, Mader JT: **Rhinocerebral Mucormycosis with Cerebral Extension Successfully Treated with Adjunctive Hyperbaric Oxygen Therapy**. Arch Otolaryngol Head Neck Surg 1988;114:791-794.

De La Paz M, Patrinely J, Marines H, et al.: **Adjunctive Hyperbaric Oxygen in the Treatment of Bilateral Cerebro-Rhino-Orbital Mucormycosis**. American Journal of Ophthalmology 1992;114:208-211.

xv. CHRONIC REFRACTORY OSTEOMYELITIS

Davis JC: **Refractory Osteomyelitis**. Problem Wounds, The Role of Oxygen 1988; Chpt. 4 Elsevier Science Publ Co., New York.

Calhoun JH, Cobos JA, Mader JT: **Does Hyperbaric Oxygen Have a Place in the Treatment of Osteomyelitis**. Orthopedic Clinics of North America 1991;22(3):467-471.

Mader JT, Brown GL: A Mechanism for the Beneficial Effect of Hyperbaric Oxygen on Staphylococcal Osteomyelitis. Underwater Physiology VII 1981:483-488.

xvi. ACUTE THERMAL BURNS

Cianci P, Leuders, HW, Lee HW, Lee H, et al.: **Hyperbaric Oxygen Therapy Reduces Length of Hospitalization in Thermal Burns**. Journal of Burn Care and Rehabilitation 1989;10: 432-435.

Cianci P, Sato R: **Adjunctive Hyperbaric Oxygen Therapy in the Treatment of Thermal Burns: A Review**. Burns 1994;20(1):5-14.

Cianci P, Williams C, Lueders H, et al.: **Adjunctive Hyperbaric Oxygen in the Treatment of Thermal Burns: An Economic Analysis**. The Journal of Burn Care & Rehabilitation 1990;11(2):140-143.

Hart GB, Oreilly RR, Broussard ND, et al.: **Treatment of Burns with Hyperbaric**

Oxygen. Surgery, Gynecology and Obstetrics 1974;139:693-696.

xvii. ACUTE EXCEPTIONAL BLOOD LOSS ANEMIA

Hart GB, Lennon PA, Strauss MB: **Hyperbaric Oxygen in Exceptional Acute Blood-Loss Anemia.** Journal of Hyperbaric Medicine 1987;2(4):205-210.

xviii. WOUND HEALING

Hammarlund C, Sundberg T: **Hyperbaric Oxygen Reduced Size of Chronic Leg Ulcers: A Randomized Double-Blind Study.** Plastic and Reconstructive Surgery 1994;93(4):829-834.

Uhl E, Sirsjo A, Haapaniem T, et al.: **Hyperbaric Oxygen Improves Wound Healing in Normal and Ischemic Skin Tissue.** Plastic and Reconstructive Surgery 1994;93(4):835-841.

Cianci P, Petrone G, Drager S, et al.: **Salvage of the Problem Wound and Potential Amputation with Wound Care and Adjunctive Hyperbaric Oxygen Therapy: An Economic Analysis.** Journal of Hyperbaric Medicine 1988;3(3):127-141.

Knighton, DR, et al: **Regulation of wound-healing angiogenesis - Effect of oxygen gradients and inspired oxygen concentration.** Surgery 1981;08:262-270.

Hunt, TK, Pai, M.P.: **The effect of varying ambient oxygen tensions on wound metabolism and collagen synthesis.** Surgery, Gynecology & Obstetrics 1972(135):561-567.

Knighton, DR et al: **Oxygen as an Antibiotic.** Arch Surg 1986;121:191-195.

xix. OUTCOME ORIENTATED TESTING

Holm, MaryAnn: **Transcutaneous Oxygen Measurement as a Predictor of Wound Healing and Response to Hyperbaric Oxygen Therapy.** Canadian Journal of Respiratory Therapy 1994; 30:182-187.

Bunt TJ, FACS, Holloway G Allen: **TcPO₂ as an accurate predictor of therapy in limb salvage.** Annals of Vascular Surgery. 1996; Vol. 10, No. 3:224-22

Sheffield PJ: **Tissue oxygen measurements with respect of soft tissue wound healing with normobaric and hyperbaric oxygen.** Hyperb Oxygen Rev 1985; 6:18-46

xx. REPERFUSION INJURIES

Lemasters JJ, Nieminen AL, Qian T, Trost LC, Herman B.: **The Mitochondrial permeability transition in toxic, hypoxic and reperfusion injury.** Mol Cell Biochem 1997 Sep; 174 (1-2): 159-65

Attkiss KJ, Suski M, Hunt TK, Buncke HJ: **Ischemic preconditioning of skeletal muscle improves tissue oxygenation during reperfusion.** J. Reconstr. Microsurg

1999 Apr; 15(3):223-8.

Weaver LK, Greenway L, Elliott CG (1988) **Controlled frostbite injury to mice. Outcome of hyperbaric oxygen therapy.** J. Hyperbaric Med 3:35-44.

Thom, SR, Strauss MB (1985) **Frostbite: pathophysiology, treatment and role of hyperbaric oxygen.** Hyperbaric Oxygen Rev. 6:99-113.

Cianci P, Petrone G, Drager S, et al: **Salvage of the Problem Wound and Potential Amputation with Wound Care and Adjunctive Hyperbaric Oxygen Therapy: An Economic Analysis.** Journal of Hyperbaric Medicine 1988; 3(3): 127-141.

CARITAS HEALTH GROUP
HYPERBARIC OXYGEN UNIT





Partners



Caritas Health Group is Alberta's largest voluntary-sector health care provider, combining leading-edge science with the values of faith-based health care. Caritas is primarily funded through Capital Health, a Regional Health Authority which coordinates an integrated, publicly funded health system for 800,000 people in the Capital Health Region.



Hyperbaric oxygen therapy is a medical treatment that is used to treat a limited but diverse series of illnesses. It is the primary treatment for disorders such as carbon monoxide poisoning, decompression sickness and arterial gas embolism. It is also an effective adjunct in a combined program involving antibiotics, dressing changes and surgery for the enhancement of healing.



DAN is a unique organization dedicated to safety, education and research in the scuba diving community. Divers Alert Network was founded in 1980 at Duke University Medical Center as recreational scuba diving's 24-hour emergency hotline for injured divers. The Misericordia is the DAN referral centre for Alberta.



COMPRU is a clinical/research centre for head and neck reconstruction and has a specific interest in the use of osseointegration biotechnology. COMPRU has registered an ISO9001 quality system for osseointegration. COMPRU was nominated as a member of the Association of Brånemark Osseointegration Centres.